

# Retinal Hemorrhages in Children

## The Role of Intracranial Pressure

Tiffany Shiau, MHS; Alex V. Levin, MD, MHS

**Objective:** To evaluate the role of intracranial pressure (ICP) in the production of retinal hemorrhage in young children.

**Design:** Review of published clinical, postmortem, and experimental research findings worldwide pertinent to our review objective. We used PubMed, MEDLINE, and Ovid Evidence-Based Medicine Reviews as well as references found in other published articles to conduct searches.

**Main Exposures:** Increased ICP from various etiologies.

**Main Outcome Measure:** Hemorrhagic retinopathy, in particular with extension to the periphery, multiple layers, and too-numerous-to-count hemorrhages. The review also considers additional intraocular findings such as retinoschisis and perimacular folds.

**Results:** In general, elevated ICP does not cause extensive hemorrhagic retinopathy. Papilledema may be associated with a small number of hemorrhages on or around the optic disc. There are isolated case reports that severe hyperacute ICP elevation, unlike the subacute pressure increase in abusive head injury, in children may rarely result in extensive retinal hemorrhage. These diagnoses are readily distinguished from child abuse.

**Conclusions:** In the absence of the few readily recognizable alternate scenarios, extensive retinal hemorrhage in very young children is not secondary to isolated elevated ICP.

*Arch Pediatr Adolesc Med.* 2012;166(7):623-628.

Published online March 5, 2012.

doi:10.1001/archpediatrics.2012.46

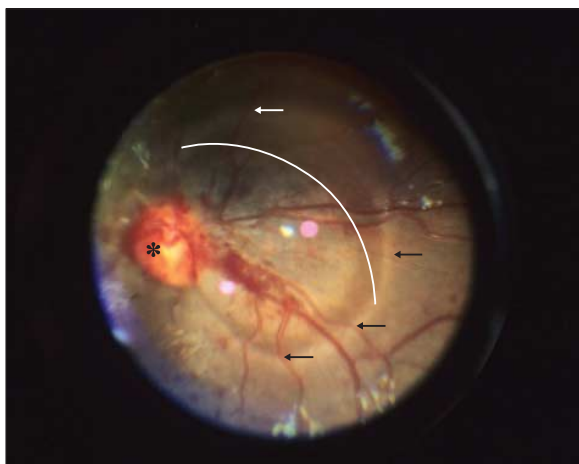
**Author Affiliations:** Jefferson Medical College, Thomas Jefferson University (Ms Shiau and Dr Levin), and Pediatric Ophthalmology and Ocular Genetics, Wills Eye Institute, (Dr Levin), Philadelphia, Pennsylvania.

**R**ETINAL HEMORRHAGE (RH) may be seen in many disorders, in particular abusive head trauma (AHT) characterized by repeated acceleration-deceleration with or without blunt head impact (shaken baby syndrome). Although we use the term AHT herein, we recognize that it is the shaken baby syndrome mechanism (as opposed to a single abusive blunt head impact, for example) that is associated specifically with hemorrhagic retinopathy. Describing RH assists in etiology recognition. The retina is a multilayered organ lining the inside of the eye, extending from the optic nerve to behind the iris. The anterior (peripheral) retinal edge is the ora serrata. Retina around the optic nerve is the peripapillary retina. The posterior pole includes the optic nerve disc, macula (generally defined as posterior retina extending out to temporal vascular arcades), fovea (center of macula), and peripapillary region (**Figure 1**). Four vortex veins mark the posterior edge of peripheral retina. The

area between the posterior pole and peripheral retina is the midperipheral retina (**Figure 2**). One can describe patterns of distribution (eg, perivascular).

Retinal hemorrhage can also be counted. When the number becomes too high to easily count, terms such as confluent, too numerous to count, or rough estimates of number (eg, 50-100) should be used. One should avoid terms such as mild, moderate, severe, or extensive. What may seem severe to someone who has never seen an RH may actually be mild to someone with more experience.

When bleeding occurs in front of the retinal layers, the hemorrhage is described as preretinal or subhyaloid (underneath the hyaloid [ie, vitreous gel]; **Figure 2**). Intraretinal RH encompasses any bleeding within retinal layers. If bleeding is within the superficial nerve fiber layer, it has a flame or splinter appearance (**Figure 2**), whereas hemorrhage into the deeper layers appear to be and are called dot or blot hemorrhage (**Figure 2**). Blot hemorrhages are relatively larger than dot



**Figure 1.** Traumatic macular retinoschisis of an infant with abusive head trauma. Photograph shows the posterior pole including the optic nerve (asterisk) and hypopigmented circumlinear retinal fold (arrows). The hump in the vessel created by the fold can be seen where the vessels cross. The arc highlights the 3-dimensional appreciation of the elevated internal limiting membrane of the retina creating a domed cavity involving the macula. There is no blood within the cavity in this child.

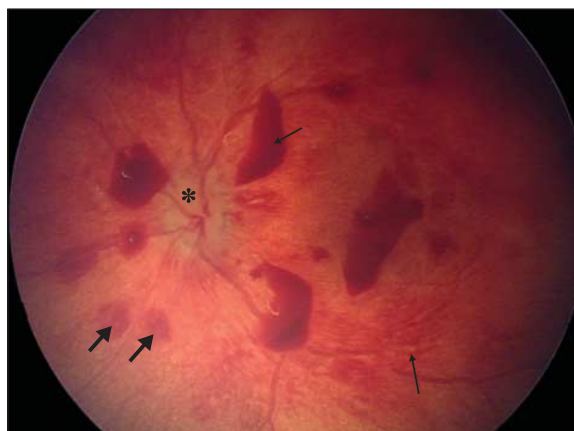hemorrhages but without objective criteria for this distinction. Bleeding under the retina is subretinal.

Retinal hemorrhages occur in approximately 85% of AHT cases.<sup>1-3</sup> More than 75% have bilateral RH.<sup>3,4</sup> In approximately two-thirds, RHs are too numerous to count, involving multiple retinal layers and covering nearly the entire retinal surface.<sup>5</sup> Retinal hemorrhages from accidental causes rarely reach the periphery, are usually confined to the posterior pole, and are few.<sup>1,2,5-7</sup> Severity of the RH correlates positively with severity of the intracranial trauma.<sup>3,8</sup>

Research using clinical cases,<sup>3,5,9</sup> autopsy cases,<sup>10-12</sup> animal models,<sup>13</sup> and finite element analysis<sup>14,15</sup> has demonstrated the importance of vitreoretinal traction in the pathogenesis of RH in AHT. In infants and young children, the adherence between vitreous and posterior pole and peripheral retina is particularly strong.<sup>1,16</sup> Repetitive acceleration-deceleration produces shearing forces sufficient to allow vitreous to pull on the retina, leading to splitting of retinal layers (traumatic retinoschisis); this is found almost solely in AHT and arising most often between the superficial internal limiting membrane and nerve fiber layer.<sup>3,4,17</sup> The same vitreoretinal traction can produce perimacular folds—elevated retinal ridges encircling the macula.<sup>18</sup> Shearing forces at vitreoretinal interface disrupted retinal vessel autoregulation in an animal model.<sup>19</sup> Retinal vessels are subject to sympathetic and parasympathetic control. Autonomic neurons are carried by cranial nerves, which may be damaged within the orbit in AHT.<sup>3,4</sup>

Despite ample evidence that repetitive and excessive acceleration-deceleration forces are required to cause the severe hemorrhagic retinopathy seen in AHT,<sup>3,5,9-15</sup> some researchers continue to contest this view with alternative theories.<sup>4</sup> When evaluating a child with RH, all differential diagnoses should be considered before concluding on a mechanism of abuse.

The hypothesis that increased intracranial pressure (ICP) can induce extensive retinal bleeding has recently been promulgated largely in the courtroom.<sup>20,21</sup> Elevated ICP is



**Figure 2.** Posterior pole of the left eye and extending into the midperiphery of the retina (at edges of image) of an infant with abusive head trauma. Image shows optic nerve (asterisk), a preretinal hemorrhage (note how it lies over a retinal vessel) (short arrows), and flame hemorrhage with characteristic linear appearance (long arrows).

present in 85% of AHT cases,<sup>22,23</sup> but it may also occur owing to other conditions including accidental trauma. If this hypothesis were true, the diagnostic specificity of RH would be reduced. Rather than being a marker for abuse, RH might reflect increased ICP regardless of the cause.

The purpose of this paper is to explore whether RH can be the result of increased ICP.

## RESULTS

### ARGUMENTS USED IN FAVOR OF RH CAUSATION BY INCREASED ICP

Papilledema is the signature ocular manifestation of increased ICP. It is thought to originate from stasis of axoplasmic flow. Retinal hemorrhage associated with papilledema is usually intraretinal, less commonly preretinal, and confined to the posterior pole.<sup>24</sup> To our knowledge, extensive RH beyond the peripapillary retina has not been reported as a manifestation of papilledema.

Optic nerve sheath is continuous with intracranial submeningeal spaces. Dilation of the sheath has been detected by ultrasound in adults with acutely elevated ICP.<sup>25</sup> Sheath enlargement has also been demonstrated in post-mortem study of patients (most likely adults given the pathologies) with acute intracranial hypertension, especially in the immediate retrobulbar portion.<sup>26</sup> In an adult diagnosed as having pseudotumor cerebri presenting with bilateral papilledema and high opening cerebrospinal fluid pressure, the sheath diameter was reduced significantly following lumbar puncture and cerebrospinal fluid pressure reduction.<sup>27</sup> Narrowing of diameter was similarly observed after pressure-reducing surgeries for 40 patients with intracranial hypertension.<sup>28</sup> Increasing cerebrospinal fluid pressure through serial intrathecal infusions in adults with cerebrospinal fluid absorption disorders led to sheath widening.<sup>29</sup> Sheath diameters in hydrocephalic children (aged 3 months to 16 years) with ventriculoperitoneal shunts<sup>30</sup> were significantly larger for those displaying clinical evidence of elevated ICP.

The hypothesis linking increased ICP to RH is largely based on the theory that pressure transmitted along the optic nerve sheath results in compression of the central retinal vein (CRV) that is found within the center of the anterior optic nerve, which in the presence of unaltered arterial inflow to the retina results in vascular ruptures.<sup>1</sup> Occlusion of CRV obstruction (CRVO) results in a characteristic fundusoscopic pattern, with tortuous and dilated retinal veins associated with large numbers of intraretinal or preretinal RH radiating out from optic nerve centripetally. Vitreous and subretinal RH is uncommon in CRVO, although RH can be seen extending to the retinal periphery.

Intraocular hemorrhage, vitreous and/or retinal, associated with intracranial bleeding is known as Terson syndrome,<sup>31</sup> which is seen in 16% to 27% of adults with subarachnoid hemorrhage (SAH) from a ruptured intracerebral aneurysm.<sup>2,30</sup> Hemorrhage inside the optic nerve sheath is common. Pathogenesis is largely unknown. One hypothesis suggests that intracranial bleeding tracks into the sheath through the submeningeal communication to the brain, resulting in compression of the optic nerve and CRV and inhibiting venous return.<sup>32</sup> In rhesus monkeys, when ICP was increased to systemic arterial pressure, ophthalmic veins became engorged and hemorrhages limited to the posterior pole occurred.<sup>33</sup> Another hypothesis suggests increased ICP from intracranial hemorrhage is transmitted down the sheath compressing the CRV.<sup>31</sup> A third hypothesis proposes that transmission of increased ICP to the sheath's subarachnoid space obstructs retinochoroidal anastomoses at the sclerodural junction.<sup>26</sup>

Two papers are often quoted in courts of law to support a link between increased ICP and RH in child abuse cases. Muller and Deck's<sup>26</sup> postmortem analysis on 46 eyes of 23 patients with intracranial hypertension revealed optic nerve sheath hemorrhage in 87%, largely due to spontaneous intracranial hemorrhage from ruptured aneurysms. Thirty-seven percent of eyes had RH, predominantly intraretinal and preretinal at or near the optic disc, with some being more peripheral. The authors suggested that sheath hemorrhage was a result of optic nerve sheath bridging and intradural vessel rupture from ICP transmitted into the sheath, with secondary compression of CRV and obstruction of retinochoroidal anastomoses, causing RH. They noted preferential nerve sheath dilation immediately retrobulbar. Vanderlinden and Chisholm<sup>34</sup> described 6 adults hospitalized for submeningeal hemorrhages: 4 with ruptured aneurysms had subhyaloid hemorrhage, 3 of which were peripapillary. There was no peripheral bleeding. All 6 had delayed vitreous hemorrhage attributed to extension of subhyaloid hemorrhages secondary to repetitive intracranial hypertensive episodes.

#### THE CASE AGAINST ICP CAUSATION OF RH IN CHILDREN

Despite the suggestions just discussed, there is abundant literature grounded in clinical data and human or animal experiments that speak to the contrary.

Large studies of victims of nonaccidental head trauma have failed to show fundusoscopic patterns characteristic of CRVO.<sup>3,5,9</sup> Although too-numerous-to-count multi-

layered (preretinal, intraretinal, and subretinal) bilateral RH extending to the periphery were commonly found, the pattern is more random than CRVO and the retinal veins typically appear normal in caliber and course.<sup>3,9</sup> Papilledema is seen in less than 10% of AHT cases despite 85% having RH.<sup>3,9</sup> There appears to be no correlation between increased ICP and the presence of RH in AHT.<sup>3</sup> Many cases of severe RH in AHT do not have intracranial hypertension.<sup>10,35</sup> Postmortem studies in AHT show optic nerve sheath hemorrhage is often discontinuous and multifocal, commonly not involving the proximal sheath.<sup>8,11,31</sup> Hemorrhagic retinopathy can occur without sheath hemorrhage.<sup>10,36</sup>

Extensive RH similar to the hemorrhagic retinopathy observed in AHT has not been observed in children with elevated ICP from nonabusive causes. Children with elevated ICP from hydrocephalus and/or shunt malfunction showed no RH.<sup>37-39</sup> Sixteen infants with spontaneous subdural hematoma associated with macrocephaly since birth and intracranial hypertension did not have severe hemorrhagic retinopathy.<sup>40</sup> In monkeys, subarachnoid space saline injections to increase ICP to systemic arterial pressure did not produce RH.<sup>33</sup> Terson syndrome is rare in nonabused children with intracranial bleeding, with a maximal incidence estimated at 8%.<sup>2</sup> Thousands of children with hypertension are examined yearly by pediatric ophthalmologists, yet reports of RH beyond that of papilledema are scarce.

The absence of clinical data in children to support the association of extensive RH with increased ICP is consistent with anatomy and physiology. The eye has points of egress for venous blood other than the CRV—the 4 vortex veins. Orbital venous drainage is unvalved and includes collaterals.<sup>41</sup> If an obstruction occurs at the cavernous sinus or optic nerve sheath from increased ICP, this should not impact overall drainage.<sup>26</sup> It was Muller and Deck who argued that even with ICP of 250 mm Hg, the cavernous sinus was not obstructed and venous flow continued at 50% of baseline.<sup>26</sup> In a study where a suction cup was attached to the eyes of children increasing intraocular pressure until high enough to collapse the CRV, CRVO hemorrhage was not observed.<sup>42</sup> Ophthalmic artery pressure may paradoxically drop when ICP is increased in monkeys.<sup>43</sup> Blocking the CRV in 6 rhesus monkeys at its exit site from the optic nerve sheath also only caused short-lived engorged and tortuous veins without hemorrhage.<sup>44</sup> Increasing ICP in human cadavers by saline infusion through ventriculostomy showed subarachnoid pressure at the posterior optic nerve sheath to be consistently higher than the anterior bulbous portion perhaps because the anterior segment is the most distensible and the thinnest.<sup>45</sup> Lastly, the retinochoroidal anastomoses lie outside the subarachnoid space near the sclerodural junction, where they are less susceptible to compression.<sup>26</sup>

There are problems with the studies by Muller et al and Vanderlinden et al. The former's claim that optic nerve sheath was most distended at the retrobulbar ampulla was not statistically analyzed. Sheath diameter 1.0 cm behind the globe was only 0.4 mm greater with intracranial hypertension than control subjects.<sup>26</sup> In addition, their findings seem not to represent pediatric patients. Al-

though ages were not provided, the high incidence of vascular pathologies are uncommonly seen in children.<sup>26,46</sup> Patients in the Vanderlinden et al study were adults with recurrent high ICP without the severe RH seen in AHT.<sup>34</sup> Attempts to extrapolate adult data to children regarding retinal vasculature are tenuous. The most common causes of RH in adults (ie, diabetes, hypertension, and sickle cell) never cause RH in the AHT age range. The healthy infant retinal blood vessel is inherently more resistant to leakage.

#### WHEN INCREASED ICP MIGHT CAUSE RH

There appears to be some unique circumstances in which increased ICP may be associated with RH. In each case, AHT is readily eliminated from differential diagnosis, but analysis of these cases may be instructive in understanding why increased ICP is not the cause of RH in other circumstances.

Although rare, isolated cases of fatal head crush injuries have had extensive RH similar to AHT. Lantz and colleagues<sup>47</sup> reported a fatal television head crush of a 14-month-old child. A 63-kg child fell on a 4-month-old infant, transmitting her weight onto the infant's head and fatally crushing him.<sup>48</sup> Watts and Obi<sup>49</sup> described a 10-week-old infant crushed between his mother's chest and a barrier when she fell forward. In these scenarios, the children developed multilayered RH extending to the periphery. Perimacular folds were noted in the first 2 infants and retinoschisis verified in 1.<sup>47-49</sup> In a series of pediatric head crush injuries, only 5 of 20 children with fundus examinations had RH.<sup>50</sup> Bleeding was largely peripapillary, except 1 with hemorrhage to the midequator and another with scattered hemorrhages to the ora serrata. No retinal folds or retinoschisis was seen.

The mechanism leading to extensive RH in these unique cases of fatal head crush injuries is unclear.<sup>51</sup> A hyperacute and extreme increase in ICP may play a role. This is different than the subacute ICP elevation in AHT. Other possibilities include direct shearing forces to the eye and orbit. Crush injuries often cause orbital fracture. Orbit examination was not reported in these cases.

Severe fatal motor vehicle collisions have occasionally resulted in severe hemorrhagic retinopathy. Autopsies of 10 children with elevated ICP showed that 8 had RH that extended to the periphery, 3 had elevated circular retinal folds, and 6 had internal limiting membrane retinoschisis, but none had deeper splitting of retinal layers.<sup>52</sup> In a case series of children with brain injuries leading to intensive care unit admissions or death, 1 of 38 in motor vehicle collisions had 15 or more preretinal RHs extending into midperiphery.<sup>53</sup> This child sustained bilateral orbital roof fractures, increasing the possibility of direct globe trauma as an etiologic factor. Funduscopic examinations of 16 children aged younger than 2 years with subdural hematoma and intracranial hypertension from traffic accidents revealed posterior pole flame RH in 3 children.<sup>54</sup> Other studies of children aged younger than 24 months with RH and severe brain injury from a motor vehicle collision lacked detailed descriptions. Almost all the children died.<sup>52,55,56</sup> Severe and sometimes repetitive (eg, motor vehicle rollovers) acceleration-

deceleration seen in some motor vehicle collisions are consistent with AHT mechanisms. A hyperacute extreme abrupt increase in ICP may also play a role in RH development.

While it is not uncommon to find severe intraocular hemorrhage in association with SAH due to ruptured aneurysms in adults (the most common form of Terson syndrome), such events are rare in young children. McLellan and colleagues<sup>57</sup> reported "extensive bilateral retinal haemorrhages and a large right subhyaloid haemorrhage" in a 6-week-old infant with large intracerebral hematoma due to a ruptured cerebral aneurysm. Postmortem examination of a 7-month-old infant with diffuse cerebral edema and SAH due to ruptured cerebral aneurysm revealed bilateral RH extending to the ora serrata.<sup>58</sup> Angiogram results prior to brain removal did not show vascular abnormalities. Diagnosis was made using histologic findings consistent with an aneurysm and a site of rupture. Bhardwaj and colleagues<sup>59</sup> observed unilateral preretinal and RH extending to the periphery in a 7-month-old infant with intracranial hypertension from ruptured aneurysm. Additional pediatric reports of hemorrhagic retinopathy from ruptured aneurysms did not provide detailed funduscopic descriptions.<sup>60-63</sup> One infant with ruptured aneurysm had "marked papilledema with multiple RH," while another had mostly flame hemorrhages with papilledema.<sup>61,63</sup> Reports of infants who died from ruptured intracranial vascular malformations showed optic nerve sheath but not RH.<sup>64,65</sup>

Only 0.5% to 4.6% of cerebral aneurysms occur in children and less than 1% of those occur before age 15 years.<sup>63,66</sup> Diagnosis is usually easily made on neuroimaging and intracranial hemorrhage patterns are different than AHT, with prominence of SAH and focal parenchymal bleeding as opposed to subdural hemorrhage and diffuse white matter changes with cerebral edema in AHT. Once again, the hyperacute increase in ICP from ruptured cerebral aneurysms differs from subacute increases in AHT.

Other causes of intracranial hypertension have been linked to RH in children on rare occasions. A ruptured arteriovenous malformation involving multiple spinal cord levels (T9-L2) led to bilateral papilledema and hemorrhagic retinopathy in a 4-year-old child.<sup>67</sup> A photograph of 1 eye showed 2 hemorrhages, 1 preretinal and 1 blot intraretinal, in the posterior pole. Forbes and colleagues<sup>68</sup> described 5 children with RH and traumatic epidural hematoma from accidents. All hemorrhages were superficial intraretinal confined to the posterior pole. Fatal purulent meningitis, likely associated with increased ICP, was associated with severe RH to the ora in 2 children, 1 of whom had a combined CRV and central retinal artery occlusion.<sup>69</sup> In another report of an infant with fatal meningitis and severe hemorrhagic retinopathy extending to the periphery, the authors pointed out that a later diagnosis of congenital disorder of glycosylation (congenital disorders of glycosylation type Ia) was responsible for clotting factor deficiency.<sup>70</sup> Coagulopathy with intracranial hypertension and RH have been reported. A 7-week-old infant with a bleeding diathesis due to a platelet defect developed subdural hemorrhage and posterior pole RH.<sup>71</sup> A severe case of idiopathic thrombocy-



topenic purpura in a 2-year-old child resulted in intracranial hemorrhage and bilateral RH.<sup>72</sup> No funduscopic details were provided. Biousse and colleagues<sup>73</sup> case series literature review revealed 2 children with anemia, isolated intracranial hypertension, papilledema, and only peripapillary RH.

In these scenarios, infection with possible necrosis of retinal vessels within the optic nerve sheath, coagulopathy, and other factors seem much more significant than ICP in causing RH. Only in severe fatal meningitis was RH extensive. Otherwise, the retinal findings in these cases are mild and nonspecific. The underlying diagnoses would be identified through usual diagnostic methods including laboratory testing and imaging, which then readily distinguish each from AHT.

## CONCLUSIONS

Increased ICP may result in papilledema with small numbers of intraretinal and preretinal RH in or around the optic nerve. The concept that extensive RH in very young children, in the absence of the few readily recognizable rare circumstances mentioned herein, is due to increased ICP is not supported by peer-reviewed published evidence or empirical experience. Literature about adults should be extrapolated to children with caution. There is some evidence based on isolated case reports in unusual circumstances that severe hyperacute ICP elevation in children may result in extensive RH. These diagnoses are readily distinguished from abuse. In most cases of AHT, elevated ICP is seen but even in this scenario, ICP appears to play only a small role, perhaps modulating the appearance of hemorrhages in a particular child along with other factors.

It may be difficult to disentangle the effects of multiple factors such as trauma, coagulopathy, and infection in the presence of increased ICP, but severe multilayered hemorrhagic retinopathy—in particular with retinoschisis, perimacular folds, and extension of hemorrhages to the ora without the readily diagnosed scenarios discussed here—is highly suspicious for AHT. However, clinicians should maintain open minds to consider how multiple factors might aggravate retinopathy in atypical circumstances.

**Accepted for Publication:** December 27, 2011.

**Published Online:** March 5, 2012. doi:10.1001/archpediatrics.2012.46

**Correspondence:** Alex V. Levin, MD, MHSc, Pediatric Ophthalmology and Ocular Genetics, Wills Eye Institute, 840 Walnut St, Ste 1210, Philadelphia, PA 19107 (alevin@wills-eye.org).

**Author Contributions:** Study concept and design: Levin. Analysis and interpretation of data: Shiao and Levin. Drafting of the manuscript: Shiao and Levin. Critical revision of the manuscript for important intellectual content: Levin. Obtained funding: Levin. Administrative, technical, and material support: Levin. Study supervision: Levin.

**Financial Disclosure:** None reported.

**Funding/Support:** This study was funded in part by the Foerderer Fund in the form of limited support for a portion of Dr Levin's salary for time allotted for research.

**Conflict of Interest:** Dr Levin has testified and reviewed cases for the defense, prosecution, and plaintiffs in child abuse cases.

## REFERENCES

- Levin AV. Retinal Haemorrhages and Child Abuse. *Recent Advances in Paediatrics*. Vol 18. London, England: Churchill Livingstone; 2000:151-219.
- Schloff S, Mullaney PB, Armstrong DC, et al. Retinal findings in children with intracranial hemorrhage. *Ophthalmology*. 2002;109(8):1472-1476.
- Morad Y, Kim YM, Armstrong DC, Huyer D, Mian M, Levin AV. Correlation between retinal abnormalities and intracranial abnormalities in the shaken baby syndrome. *Am J Ophthalmol*. 2002;134(3):354-359.
- Levin AV. Retinal hemorrhage in abusive head trauma. *Pediatrics*. 2010;126(5):961-970.
- Bechtel K, Stoessel K, Leventhal JM, et al. Characteristics that distinguish accidental from abusive injury in hospitalized young children with head trauma. *Pediatrics*. 2004;114(1):165-168.
- Christian CW, Taylor AA, Hertle RW, Duhaime AC. Retinal hemorrhages caused by accidental household trauma. *J Pediatr*. 1999;135(1):125-127.
- Vinchon M, Defoort-Dhellemmes S, Desurmont M, Dhellemmes P. Accidental and nonaccidental head injuries in infants: a prospective study. *J Neurosurg*. 2005;102(4)(suppl):380-384.
- Green MA, Lieberman G, Milroy CM, Parsons MA. Ocular and cerebral trauma in non-accidental injury in infancy: underlying mechanisms and implications for paediatric practice. *Br J Ophthalmol*. 1996;80(4):282-287.
- Kivlin JD, Simons KB, Lazowitz S, Ruttum MS. Shaken baby syndrome. *Ophthalmology*. 2000;107(7):1246-1254.
- Munger CE, Peiffer RL, Bouldin TW, Kylstra JA, Thompson RL. Ocular and associated neuropathologic observations in suspected whiplash shaken infant syndrome: a retrospective study of 12 cases. *Am J Forensic Med Pathol*. 1993;14(3):193-200.
- Wyganski-Jaffe T, Levin AV, Shafiq A, et al. Postmortem orbital findings in shaken baby syndrome. *Am J Ophthalmol*. 2006;142(2):233-240.
- Matschke J, Püschel K, Glatzel M. Ocular pathology in shaken baby syndrome and other forms of infantile non-accidental head injury. *Int J Legal Med*. 2009;123(3):189-197.
- Bonnier C, Mespès B, Carpentier S, Henin D, Gressens P. Delayed white matter injury in a murine model of shaken baby syndrome. *Brain Pathol*. 2002;12(3):320-328.
- Cirovic S, Bhole RM, Hose DR, Howard IC, Lawford PV, Parsons MA. Mechanistic hypothesis for eye injury in infant shaking: an experimental and computational study. *Forensic Sci Med Pathol*. 2005;1(1):53-59. doi:10.1385/FSPM:1:1:053.
- Rangarajan N, Kamalakannan SB, Hasija V, et al. Finite element model of ocular injury in abusive head trauma. *J AAPOS*. 2009;13(4):364-369.
- Sturm V, Landau K, Menke MN. Optical coherence tomography findings in shaken baby syndrome. *Am J Ophthalmol*. 2008;146(3):363-368.
- Greenwald MJ, Weiss A, Oesterle CS, Friendly DS. Traumatic retinoschisis in battered babies. *Ophthalmology*. 1986;93(5):618-625.
- Massicotte SJ, Folberg R, Torczynski E, Gilliland MG, Luckenbach MW. Vitreoretinal traction and perimacular retinal folds in the eyes of deliberately traumatized children. *Ophthalmology*. 1991;98(7):1124-1127.
- Nagaoka T, Sakamoto T, Mori F, Sato E, Yoshida A. The effect of nitric oxide on retinal blood flow during hypoxia in cats. *Invest Ophthalmol Vis Sci*. 2002;43(9):3037-3044.
- Al-Bayati M. Analysis of causes that led to toddler Alexa Marie Shearer's cardiac arrest and death in November, 1999. *Med Veritas*. 2004;1(1):86-116.
- Dyer C. Doctors in shaken baby syndrome case are accused of "scientific prejudice." *BMJ*. 2010;340:c1989. doi:10.1136/bmj.c1989.
- Bonnier C, Nassogne MC, Evrard P. Outcome and prognosis of whiplash shaken infant syndrome: late consequences after a symptom-free interval. *Dev Med Child Neurol*. 1995;37(11):943-956.
- Feldman KW, Bethel R, Shugerman RP, Grossman DC, Grady MS, Ellenbogen RG. The cause of infant and toddler subdural hemorrhage: a prospective study. *Pediatrics*. 2001;108(3):636-646.
- Keane JR. Papilledema with unusual ocular hemorrhages. *Arch Ophthalmol*. 1981;99(2):262-263.
- Hansen HC, Helmke K, Kunze K. Optic nerve sheath enlargement in acute intracranial hypertension. *Neuro-Ophthalmology*. 1994;14(6):345-354. doi:10.3109/01658109409024061.
- Muller PJ, Deck JH. Intracocular and optic nerve sheath hemorrhage in cases of sudden intracranial hypertension. *J Neurosurg*. 1974;41(2):160-166.
- Galetta S, Byrne SF, Smith JL. Echographic correlation of optic nerve sheath size and cerebrospinal fluid pressure. *J Clin Neuroophthalmol*. 1989;9(2):79-82.

28. Gangemi M, Cennamo G, Maiuri F, D'Andrea F. Echographic measurement of the optic nerve in patients with intracranial hypertension. *Neurochirurgia (Stuttg)*. 1987;30(2):53-55.
29. Hansen HC, Helmke K. Validation of the optic nerve sheath response to changing cerebrospinal fluid pressure: ultrasound findings during intrathecal infusion tests. *J Neurosurg*. 1997;87(1):34-40.
30. Newman WD, Hollman AS, Dutton GN, Carachi R. Measurement of optic nerve sheath diameter by ultrasound: a means of detecting acute raised intracranial pressure in hydrocephalus. *Br J Ophthalmol*. 2002;86(10):1109-1113.
31. Ko F, Knox DL. The ocular pathology of Terson's syndrome. *Ophthalmology*. 2010; 117(7):1423-1429, e2.
32. Walsh FB, Hedges TR Jr. Optic nerve sheath hemorrhage. *Am J Ophthalmol*. 1951; 34(4):509-527.
33. Hedges TR, Weinstein JD, Crystle CD. Orbital vascular response to acutely increased intracranial pressure in the rhesus monkey. *Arch Ophthalmol*. 1964; 71:226-237.
34. Vanderlinden RG, Chisholm LD. Vitreous hemorrhages and sudden increased intracranial pressure. *J Neurosurg*. 1974;41(2):167-176.
35. Luerssen TG, Huang JC, McLone DG. Retinal hemorrhages, seizures, and intracranial hemorrhages: relationships and outcomes in children suffering traumatic brain injury. *Concepts Pediatr Neurosurg*. 1991;11:87-94.
36. Riffenburgh RS, Sathyavagiswaran L. Ocular findings at autopsy of child abuse victims. *Ophthalmology*. 1991;98(10):1519-1524.
37. Tzekov C, Cherninkova S, Gudeva T. Neuroophthalmologic symptoms in children treated for internal hydrocephalus. *Pediatr Neurosurg*. 1991-1992;17 (6):317-320.
38. Nazir S, O'Brien M, Qureshi NH, Slape L, Green TJ, Phillips PH. Sensitivity of papilledema as a sign of shunt failure in children. *J AAPOS*. 2009;13(1):63-66.
39. Bhardwaj G, Jacobs M, Martin F, et al. Retinal findings in infants following non-traumatic acute rise in intracranial pressure. *Clin Experiment Ophthalmol*. 2010; 38(suppl 2):19.
40. Vinchon M, Delestret I, DeFoort-Dhellemmes S, Desurmont M, Noulé N. Subdural hematoma in infants: can it occur spontaneously? data from a prospective series and critical review of the literature. *Childs Nerv Syst*. 2010;26(9):1195-1205.
41. Zhang J, Stringer MD. Ophthalmic and facial veins are not valveless. *Clin Experiment Ophthalmol*. 2010;38(5):502-510.
42. Firsching R, Schütze M, Motschmann M, Behrens-Baumann W. Venous ophthalmodynamometry: a noninvasive method for assessment of intracranial pressure. *J Neurosurg*. 2000;93(1):33-36.
43. Hedges TR, Weinstein JD. Cerebrovascular responses to increased intracranial pressure. *J Neurosurg*. 1964;21:292-297.
44. Hayreh SS. Occlusion of the central retinal vessels. *Br J Ophthalmol*. 1965;49(12): 626-645.
45. Liu D, Kahn M. Measurement and relationship of subarachnoid pressure of the optic nerve to intracranial pressures in fresh cadavers. *Am J Ophthalmol*. 1993; 116(5):548-556.
46. Hetts SW, Narvid J, Sanai N, et al. Intracranial aneurysms in childhood: 27-year single-institution experience. *AJNR Am J Neuroradiol*. 2009;30(7):1315-1324.
47. Lantz PE, Sinal SH, Stanton CA, Weaver RG Jr. Perimacular retinal folds from childhood head trauma. *BMJ*. 2004;328(7442):754-756.
48. Lueder GT, Turner JW, Paschall R. Perimacular retinal folds simulating nonaccidental injury in an infant. *Arch Ophthalmol*. 2006;124(12):1782-1783.
49. Watts P, Obi E. Retinal folds and retinoschisis in accidental and non-accidental head injury. *Eye (Lond)*. 2008;22(12):1514-1516.
50. Gnanaraj L, Gilliland MG, Yahya RR, et al. Ocular manifestations of crush head injury in children. *Eye (Lond)*. 2007;21(1):5-10.
51. Levin AV. Retinal hemorrhages of crush head injury: learning from outliers. *Arch Ophthalmol*. 2006;124(12):1773-1774.
52. Kivlin JD, Currie ML, Greenbaum VJ, Simons KB, Jentzen J. Retinal hemorrhages in children following fatal motor vehicle crashes: a case series. *Arch Ophthalmol*. 2008;126(6):800-804.
53. Keenan HT, Runyan DK, Marshall SW, Nocera MA, Merten DF. A population-based comparison of clinical and outcome characteristics of young children with serious inflicted and noninflicted traumatic brain injury. *Pediatrics*. 2004;114 (3):633-639.
54. Vinchon M, Noizet O, Defoort-Dhellemmes S, Soto-Ares G, Dhellemmes P. Infantile subdural hematomas due to traffic accidents. *Pediatr Neurosurg*. 2002; 37(5):245-253.
55. Duhaime AC, Alario AJ, Lewander WJ, et al. Head injury in very young children: mechanisms, injury types, and ophthalmologic findings in 100 hospitalized patients younger than 2 years of age. *Pediatrics*. 1992;90(2, pt 1):179-185.
56. Johnson DL, Braun D, Friendly D. Accidental head trauma and retinal hemorrhage. *Neurosurgery*. 1993;33(2):231-234, discussion 234-235.
57. McLellan NJ, Prasad R, Punt J. Spontaneous subhyaloid and retinal haemorrhages in an infant. *Arch Dis Child*. 1986;61(11):1130-1132.
58. Mena OJ, Paul I, Reichard RR. Ocular findings in raised intracranial pressure: a case of Terson syndrome in a 7-month-old infant. *Am J Forensic Med Pathol*. 2011;32(1):55-57.
59. Bhardwaj G, Jacobs MB, Moran KT, Tan K. Terson syndrome with ipsilateral severe hemorrhagic retinopathy in a 7-month-old child. *J AAPOS*. 2010;14(5): 441-443.
60. Vapalahti PM, Schugk P, Tarkkanen L, af Björkstén G. Intracranial arterial aneurysm in a three-month-old infant: case report. *J Neurosurg*. 1969;30(2): 169-171.
61. Crisostomo E, Leaton E, Rosenblum E. Features of intracranial aneurysms in infants and report of a case. *Dev Med Child Neurol*. 1986;28(1):68-72.
62. Kanaan I, Lasjaunias P, Coates R. The spectrum of intracranial aneurysms in pediatrics. *Minim Invasive Neurosurg*. 1995;38(1):1-9.
63. Tekköt IH, Ventureyra EC. Spontaneous intracranial hemorrhage of structural origin during the first year of life. *Childs Nerv Syst*. 1997;13(3):154-165.
64. Weissgold DJ, Budenz DL, Hood I, Rorke LB. Ruptured vascular malformation masquerading as battered/shaken baby syndrome: a nearly tragic mistake. *Surv Ophthalmol*. 1995;39(6):509-512.
65. Budenz DL, Farber MG, Mirchandani HG, Park H, Rorke LB. Ocular and optic nerve hemorrhages in abused infants with intracranial injuries. *Ophthalmology*. 1994; 101(3):559-565.
66. Wojtacha M, Bazowski P, Mander M, Krawczyk I, Rudnik A. Cerebral aneurysms in childhood. *Childs Nerv Syst*. 2001;17(1-2):37-41.
67. Clark RS, Orr RA, Atkinson CS, Towbin RB, Pang D. Retinal hemorrhages associated with spinal cord arteriovenous malformation. *Clin Pediatr (Phila)*. 1995; 34(5):281-283.
68. Forbes BJ, Cox M, Christian CW. Retinal hemorrhages in patients with epidural hematomas. *J AAPOS*. 2008;12(2):177-180.
69. Lopez JP, Roque J, Torres J, Levin AV. Severe retinal hemorrhages in infants with aggressive, fatal *Streptococcus pneumoniae* meningitis. *J AAPOS*. 2010; 14(1):97-98.
70. Ong BB, Gole GA, Robertson T, McGill J, de Lore D, Crawford M. Retinal hemorrhages associated with meningitis in a child with a congenital disorder of glycosylation. *Forensic Sci Med Pathol*. 2009;5(4):307-312.
71. Russell-Eggitt IM, Thompson DA, Khair K, Liesner R, Hann IM. Hermansky-Pudlak syndrome presenting with subdural haematoma and retinal haemorrhages in infancy. *J R Soc Med*. 2000;93(11):591-592.
72. Woerner SJ, Abildgaard CF, French BN. Intracranial hemorrhage in children with idiopathic thrombocytopenic purpura. *Pediatrics*. 1981;67(4):453-460.
73. Bioussé V, Rucker JC, Vignal C, Crassard I, Katz BJ, Newman NJ. Anemia and papilledema. *Am J Ophthalmol*. 2003;135(4):437-446.