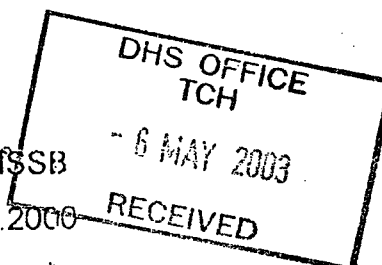


Autopsy No: A45144PPM No: 57-00Name: Lucy Crawford

**NORTHERN IRELAND REGIONAL PERINATAL/PAEDIATRIC PATHOLOGY
SERVICE, DEPARTMENT OF PATHOLOGY
ROYAL GROUP OF HOSPITALS TRUST, BELFAST**

POST MORTEM REPORT

Name: Lucy CrawfordA. No: A45144Hospital No: CH461358PPM No: 57-00Age: 18 months (dob: 5.11.98) Sex: F Health Board: WHSSBMothers Name: May CrawfordDate of PM: 14.04.2000Ward: PICU Hospital: RBHSCClinician: Dr D HanrahanPathologist: Dr M D O'HaraTotal No. of Pages: 9**Final Anatomical Summary**

1. History of acute 24-36 hour history of vomiting/diarrhoeal illness with dehydration and drowsiness 14.4.2000.
2. History of seizure at 0300 hours 13.4.2000, pupils fixed and dilated following intubation.
3. Relatively little congestion with some distension of large and small intestine with gas and clear fluid.
4. Extensive bilateral bronchopneumonia.
5. Swollen brain with generalised oedema and early necrosis
6. Heart given for valve transplantation purposes.

Commentary

The history is of a child of approximately 18 months old collapsing following an episode of seizure in the course of an acute vomiting and diarrhoeal illness. At autopsy a large number of samples were taken for culture techniques. None of these had been positive, in particular intestinal contents and faeces showed no significant growth and there was no growth from liver, trachea or right lung. It is noted however in samples taken clinically that enterovirus PCR was positive on a number of occasions. EM studies were negative. Toxicological tests were negative and serology for some of the more common viral diseases of infancy such as mumps, measles, HSV, VZV and CMV are all negative. Histology of the bowel reveals relatively minor changes. There was no evidence of significant ulceration in the small intestine. The inflammatory cell component within the lamina propria is at the upper limit of normal. It is known that some of the acute conditions associated with vomiting and diarrhoea do not always cause serious structural abnormalities within the intestine, they tend to be more of a toxic phenomenon and autopsy certainly has not shown evidence of any of the more serious conditions such as salmonella or the like.

LC- SLT

Autopsy No: A45144PPM No: 57-00Name: Lucy Crawford

The autopsy also revealed an extensive bronchopneumonia. This was well developed and well established and certainly gives the impression of having been present for some 24 hours at least. Unfortunately swabs taken from the lungs were unsuccessful and did not grow and there is no doubt that this pneumonic lesion within the lungs has been important as the ultimate cause of death, the changes being widespread throughout both lungs. The pneumonia could be possibly prior to the original disease presentation but equally could have been induced during the time of seizure and collapse. The changes seen in the brain are consistent with an acute hypoxic insult and there is no evidence of any underlying infective congenital or structural abnormality of the brain tissue.

Signature:Date:

LC- SLT

Autopsy No: A45144PPM No: 57-00Name: Lucy Crawford

Clinical History

Infant aged 18 months with a history of acute illness, vomiting then diarrhoea for 24-36 hours. Admitted to the Erne Hospital 12.4.00. Clinically dehydrated and drowsy. Given IV fluids. Seizure at 0300 hours on 13.4.00. Unresponsive afterwards. Pupils fixed and dilated. Intubated by anaesthetist and transferred to RBHSC. Arrived in PICU 0745 hours on 13.4.00. No responses. Brain stem tests at 0850 hours and 1030 hours 13.4.00. Both negative. No past medical history of note – healthy toddler on no medication. Extubated at 1300 hours on 13.4.00. No heart beat at 13.15 hours. Investigations (Erne Hospital) Na 136-126. CT Scan (RBHSC) 13.4.00 – obliteration of basal cisterns. EEG – isoelectric pattern 13.4.00. Clinical Diagnosis: Dehydration and hyponatraemia. Cerebral oedema – acute coning and brain stem death. (Clinical History provided by Dr Caroline Stewart, Specialist Registrar, Paediatrics, RBHSC).

External Appearances and Body Measurements

The body is that of a 12 kg infant measuring 73 cm in length. There appears to be good general nutrition with proportionate growth and no evidence of any external dysmorphic or congenital malformation. There is no evidence of lesions such as polydactyly or syndactyly. No simian creases are identified. There is no evidence of cleft lip or palate. The external genitalia are those of a female infant and normal for the stated age.

Internal Examination

Body Cavities:

On opening the body cavities no effusions are identified.

Cardiovascular System:

The heart has been donated at the request of the parents for either transplant or cardiac valve donation and is given in its entirety to the local transplant team. Externally it showed no abnormality. Its form was normal with no features to indicate hypertrophy, haemorrhage or other significant external lesion.

Respiratory System:

The right lung weighs 88.8 g. The left lung weighs 68.9 g. The pleura of each is thin and translucent. On sectioning no abnormalities of form are identified. There is however significant congestion and oedema with a suggestion of consolidation, especially over the right lung. The trachea shows congestion of the mucosa. The larynx and epiglottis are unremarkable.

Genito Urinary System:

The kidneys weigh 25.3 and 24.9 g, left and right respectively. Externally and on sectioning no significant abnormalities are identified. The cortical surfaces are smooth. There are no cysts. The renal pelves and ureters are not distended or dilated. The

LC- SLT

Autopsy No: A45144**PPM No:** 57-00**Name:** Lucy Crawford

bladder is unremarkable. The uterus, cervix and ovaries show appearances appropriate for the age of the child.

Gastro Intestinal System:

The liver weighs 365 g. Normal appearances are identified externally with no evidence of tumours, haemorrhage or other abnormality. The gall bladder and extra-hepatic biliary tree are normal. Section shows a mildly congested appearance with no evidence of fatty change. No fibrosis, cystic change or calcification is seen. The pancreas is normally situated and shows no abnormality. The oesophagus is unremarkable. No ulceration is identified. The stomach contains gas. On opening the stomach no significant mucosal lesion is identified. No ulceration is identified in the duodenum. Externally there is some mild distension of the small and large intestine with gas and clear fluid but on opening no significant ulceration is identified with no obvious congestive process. Payers patches are not unduly prominent. The regional mesenteric nodes are easily identifiable but not grossly enlarged.

Endocrine System:

The adrenals weigh 2.9 and 3.2 g, left and right respectively. Sectioning shows no evidence of haemorrhage. No cysts or tumours are identified. Normal structure is present in the thyroid gland.

Haemopoietic & Lymphoreticular System:

The spleen is 18.9 g. The capsule is smooth. Sectioning shows no significant abnormality. The thymus weighs 6 g. No external abnormalities are identified. Sectioning confirms a pale red grey tissue.

Skeletal System:

No skeletal abnormalities are identified. The muscle groups are normally situated and of reasonable proportions. No structural abnormalities are identified.

Central Nervous System:

The brain weighs 1060 g. It shows the features of generalised cerebral oedema with evidence of mild uncal herniation and some grooving in the tonsillar regions. Sectioning confirms the presence of diffuse oedematous change but there is no evidence of haemorrhage. No tumours or cysts are identified. The meninges are unremarkable with no evidence of haemorrhage. The cranium is unremarkable in appearance.

Autopsy No: A45144PPM No: 57-00Name: Lucy CrawfordHistology:

Lungs: The main feature in the lungs is the presence of a well developed bronchopneumonia. This seems to effect the right more than the left side but pneumonic changes are also noted on the left side. The lungs contain an inflammatory exudate of neutrophils and fibrin distributed in a lobular fashion associated with congestion and oedema. Inflammatory infiltrate extends into some of the larger airways. There is no evidence of granulomatous inflammation. No obvious organisms are identified and in particular fungi are not apparent.

Liver: The lobular pattern of the liver is normal. Extra-medullary haemopoiesis is not a feature. Mild congestive changes are identified. There is no evidence of fatty change. The portal tracts are unremarkable. Extra-medullary haemopoiesis is not a feature.

Spleen: The splenic parenchyma shows obvious malphigian bodies with well formed lymphoid germinal centres. There is no evidence to suggest a hyperreactive state. No granulomata are identified.

Pancreas: Normal structure is identified of both acinar tissues and islets. No evidence of an infective process is identified. There are no viral inclusions.

Adrenals: Normal cortico-medullary demarcation is identified. There are some features suggestive of mild stress affecting the cortical tissues but no evidence of medullary haemorrhage, necrosis or other significant abnormalities are identified.

Kidneys: Normal structure is seen. Glomerulogenesis is normal. There are no cysts and no infective process is present. There are mild oedematous changes of tubules but these are not thought to be pathologically significant.

Ovary & Uterus: Normal structure identified.

Thyroid: Normal.

Trachea: The mucosa is essentially unremarkable. No evidence of significant inflammation is identified.

Stomach: There is no evidence of ulceration or other significant inflammatory lesion.

Small & Large Intestine: Sections taken from the bowel confirm the presence of well formed villi. Within the lamina propria inflammatory cells are present at what are perhaps the upper limits of normal. No obvious areas of ulceration can be seen. There is no evidence of infestation. Viral inclusions are not a feature. There are no granulomata. The populations of inflammatory cells present do not show an excess of any particular type.

Mesenteric Lymph Nodes: These show relatively normal follicular structure. There is no evidence of significant hypoplastic change. Granulomata are not identified. No obvious viral inclusions or specific inflammatory features are noted.

Pituitary: Normal.

LC- SLT

Autopsy No: A45144PPM No: 57-00Name: Lucy Crawford

Brain: Sections are taken from brainstem, cerebellum, frontal, occipital, temporal, cortex and basal ganglia. The feature in all sections is that of widespread generalised pericellular oedema with early neuronal changes. All of these are consistent with the history of acute cerebral hypoxia having occurred shortly before death. In one section taken from basal ganglia there are a few very tiny areas of spotty calcium deposition. This may indicate an episode of damage of some considerable time in the past but it is not considered important. No tumour is identified anywhere in the sections. No evidence of meningitis is noted.

LC- SLT

Autopsy No: A45144

PPM No: 57-00

Name: Lucy Crawford

Special Investigations

Photographs:

Photographs of the body have been taken and these are on record in the Department of Pathology, RGHT.

Radiology:

Post mortem radiology has been performed. The x-rays are on record in the Department of Pathology, RGHT.

Chromosomes:

Chromosomal analysis was not carried out.

Other Investigations:

Swabs were taken from lungs, trachea, liver, faeces, sputum and intestine. No growth was noted.

LC- SLT

Autopsy No: A45144PPM No: 57-00Name: Lucy Crawford

Age: 18 months

Weight: 12 kg.

CH 73 cm

ORGAN WEIGHTS	CASE		EXPECTED
	Left	Right	
HEART	Heart donated		
LUNGS	68.9 g	88.8 g	
SPLEEN	18.9 g		
LIVER	365 g		
ADRENALS	3.2 g	2.9 g	
KIDNEYS	24.9 g	25.3 g	
THYMUS	6 g		
BRAIN	1060 g		

Ratios: Brain:Liver (N = 2- 4:1)
 Lungs:Heart (N = 2- 4:1)
 Liver:Heart (N = 4- 7:1)
 Lungs:Body (N=>0.015 if<28 wks,>0.12 if>28wks)
 Brain Gyral Pattern : weeks gestation

Heart:

TV diam mm MV diam mm FO diam mm
 PV diam mm AV diam mm PDA diam mm

Placenta:

N/A.

LC- SLT

Autopsy No: A45144PPM No: 57-00Name: Lucy Crawford

**NORTHERN IRELAND REGIONAL PERINATAL/PAEDIATRIC
PATHOLOGY SERVICE DEPARTMENT OF PATHOLOGY
ROYAL GROUP OF HOSPITALS TRUST, BELFAST**

POST MORTEM REPORT

Name: Lucy CrawfordA. No: A45144Hospital No: CH461358PPM No: 57-00Age: 18 months (dob: 5.11.98) Sex: F Health Board: WHSSBMothers Name: May CrawfordDate of PM: 14.04.2000Ward: PICU Hospital: RBHSCClinician: Dr D HanrahanPathologist: Dr M D O'HaraTotal No. of Pages: 9

Provisional Anatomical Summary:

7. History of acute 24-36 hour history of vomiting/diarrhoeal illness with dehydration and drowsiness 14.4.2000.
8. History of seizure at 0300 hours 13.4.2000, pupils fixed and dilated following intubation.
9. Relatively little congestion with some distension of large and small intestine with gas and clear fluid, patchy pulmonary congestion, pulmonary oedema.
10. Swollen brain with generalised oedema, brain to be further described following fixation.
11. Heart given for valve transplantation purposes.

Signature:Date: 17.04.2000

LC- SLT

Autopsy No: A45144PPM No: 57-00Name: Lucy Crawford

Pathologist: Dr. M D O'Hara

Date of PM: 14.4.2000

Grade: Consultant Pathologist

Supervised by: N/A

Date of Provisional Report: 17.4.00

Date of Final Report: 12.06.2000

Placenta Received:

N/A

Photographs:

Yes

Full body / face / other

Internal Organs: *

P/No:

Radiology:

Yes

AP / Lateral

Radiology Report - No

Bacteriology/Virology

Yes - swabs

Report No:

Chromosomes:

No

Tissue Culture

No

Neuropathology

No

Metabolic Investigations:

No

Electron Microscopy

Yes

Report No:

Tissues Snap Frozen:

No

Final Action:

Mount -

Teaching -

Control -

LC- SLT